

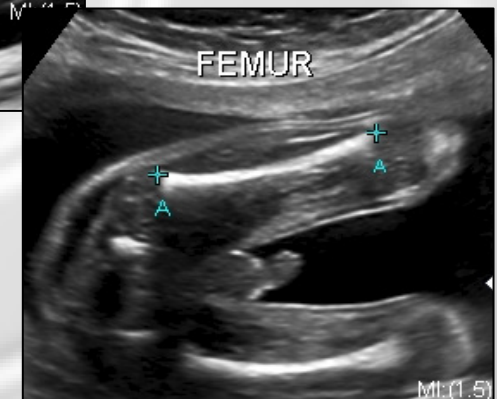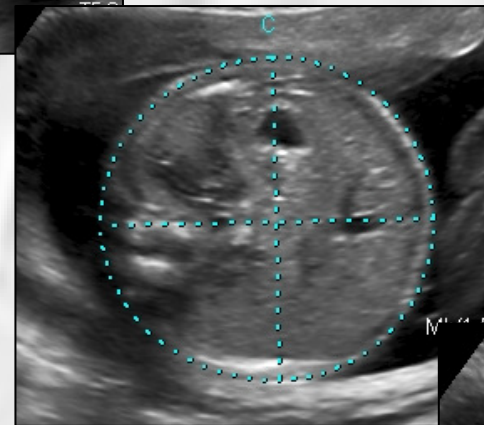
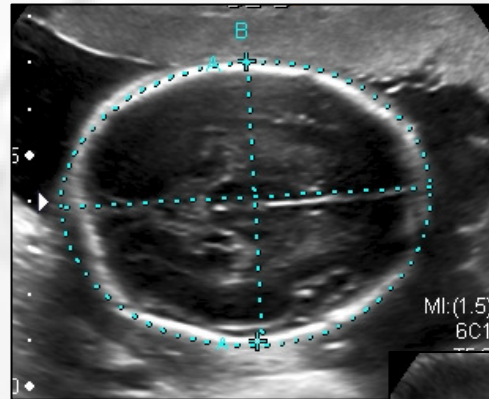


ROTINA MÍNIMA DO ESTUDO MORFOLÓGICO FETAL DE IIº TRIMESTRE

Dr. Jorge Telles

Biometria Fetal Básica


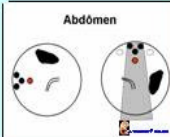


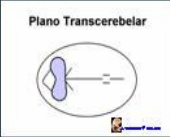

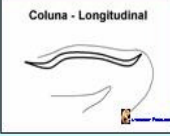


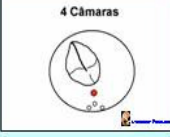





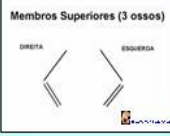
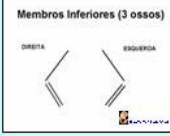

- Cabeça
 - Diâmetro Biparietal
 - Circunferência Cefálica
- Tronco
 - Circunferência Abdominal
- Membros
 - Comprimento Fêmur



Proposta:

18 planos essenciais de aquisição de imagens na ultra-sonografia, com o objetivo de avaliar a anatomia fetal e biometria ampliada

Medicina-Fetal.net ESTUDO MORFOLÓGICO FETAL BÁSICO Jorge Tellez, 2002

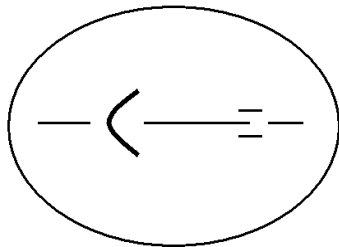
Plano Transtalâmico 	Abdômen 	Fêmur 
Plano Transventricular 	Plano Transcerebelar 	Lábios e Narinas 
Coluna - Longitudinal 	Coluna - Transverso 	Parede Abdominal 
4 Câmaras 	VE e Aorta 	VD e Art. Pulmonar 
Estômago e Diafragma 	Arco Aórtico 	Rins e Bexiga 
Membros Superiores (3 ossos) DIREITA ESQUERDA 	Membros Inferiores (3 ossos) DIREITA ESQUERDA 	Orientação dos Pés DIREITO ESQUERDO 

Modificado de: Royal College of Obstetricians and Gynaecologists, *Ultrasound Screening for Fetal Abnormalities, London, Supplement July 2000*

ESTUDO MORFOLÓGICO FETAL BÁSICO

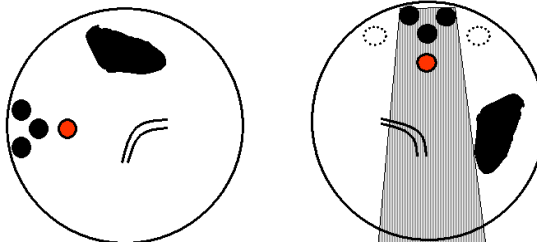
I Etapa – Biometria Básica

Plano Transtalâmico



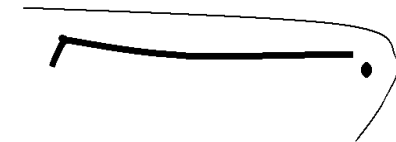
Medicina-Fetal.net

Abdômen



Medicina-Fetal.net

Fêmur

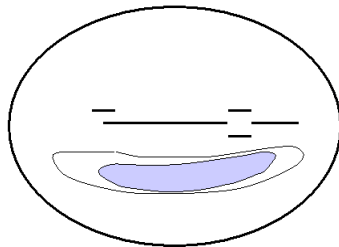


Medicina-Fetal.net

ESTUDO MORFOLÓGICO FETAL BÁSICO

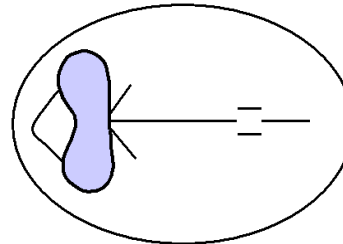
II Etapa – Encéfalo e Face

Plano Transventricular



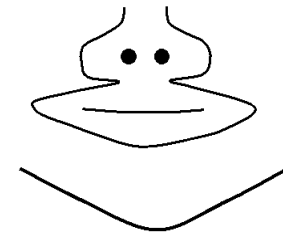
Medicina-Fetal.net

Plano Transcerebelar



Medicina-Fetal.net

Lábios e Narinas

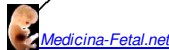


Medicina-Fetal.net

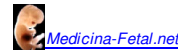
ESTUDO MORFOLÓGICO FETAL BÁSICO

III Etapa – Superfície Fetal

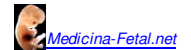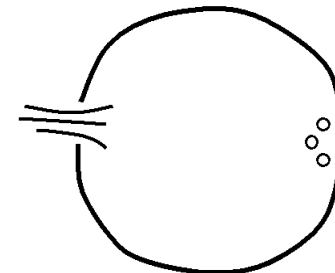
Coluna - Longitudinal



Coluna - Transverso



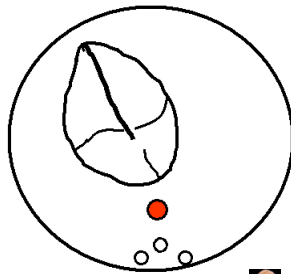
Parede Abdominal



ESTUDO MORFOLÓGICO FETAL BÁSICO

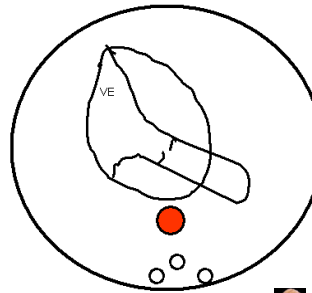
IV Etapa – Coração

4 Câmaras



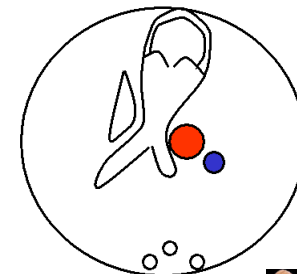
Medicina-Fetal.net

VE e Aorta



Medicina-Fetal.net

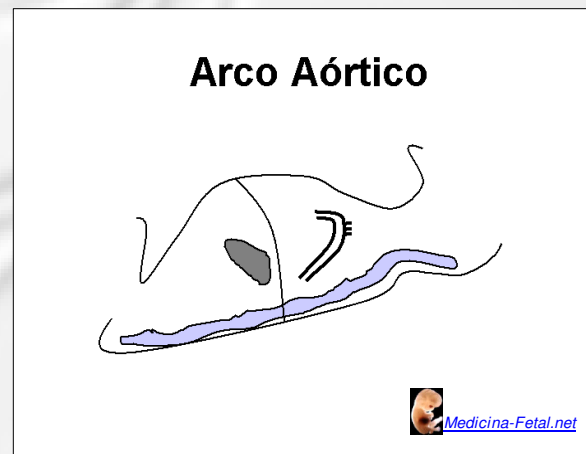
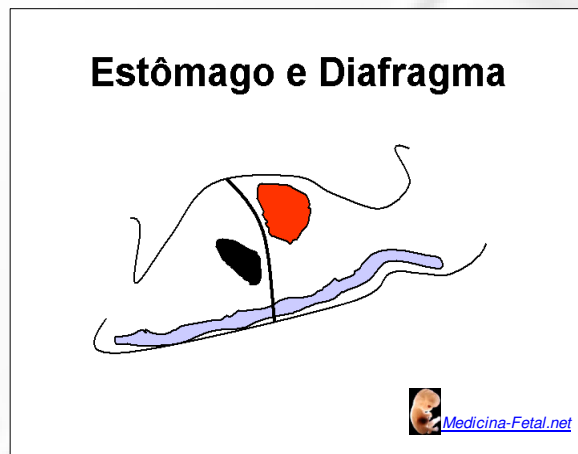VD e Art. Pulmonar



Medicina-Fetal.net

ESTUDO MORFOLÓGICO FETAL BÁSICO

V Etapa – Tronco Fetal



Como resumo mnemônico, na avaliação do tronco pode-se utilizar as letras do alfabeto (em português), como já consagrado na avaliação do trauma e outras sistematizações para suporte de vida:

A) aorta

B) bexiga

C) coração

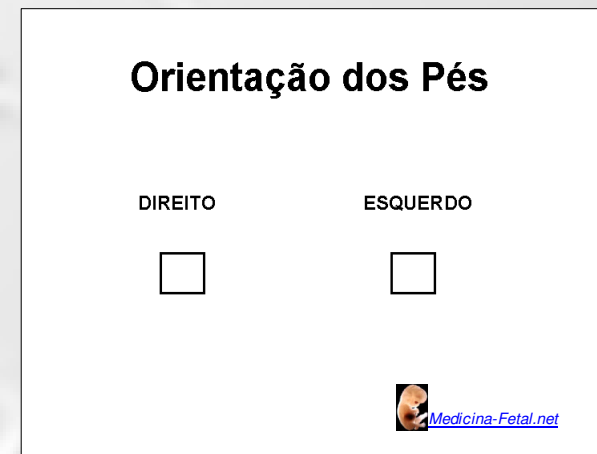
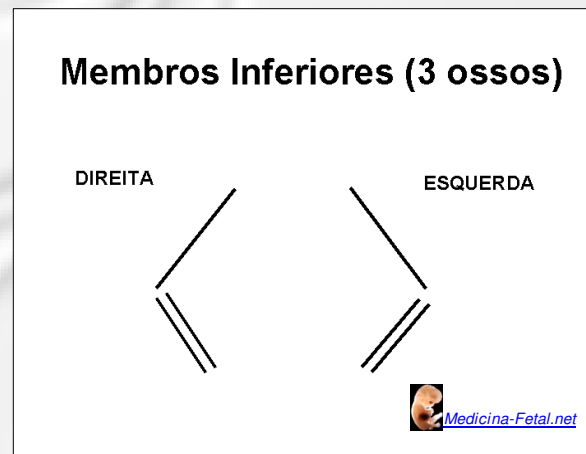
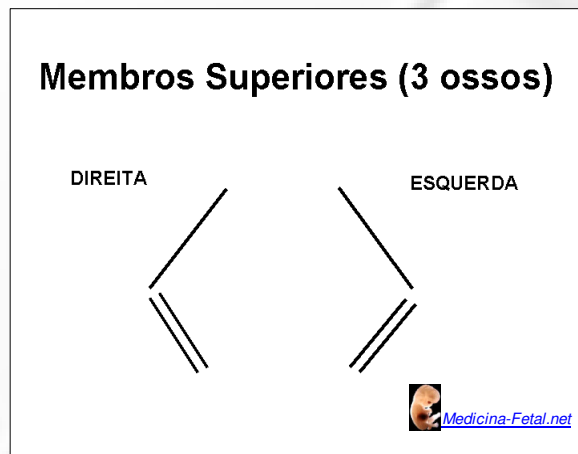
D) diafragma

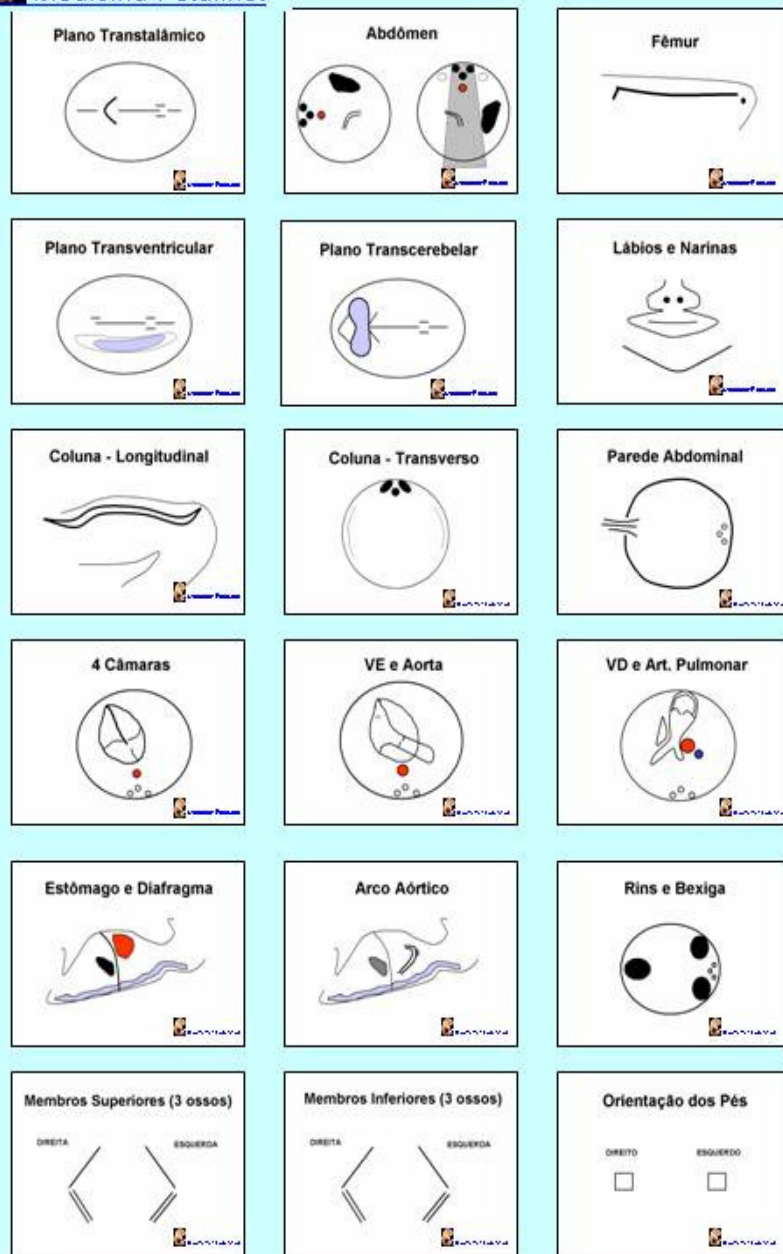
E) estômago

F) fígado

ESTUDO MORFOLÓGICO FETAL BÁSICO

VI Etapa – Membros





Modificado de: Royal College of Obstetricians and Gynaecologists, *Ultrasound Screening for Fetal Abnormalities*, London, Supplement July 2000

Outras avaliações do exame obstétrico normal:

- avaliação da placenta
- líquido amniótico
- cordão umbilical
- frequência cardíaca
- posição e atividade motora fetal

www.medicina-fetal.net